

Minimally Invasive Approach for the Treatment of Lateral Lumbar Disc Herniations. Technique and Results

Author

E. Kogias¹, V. I. Vougioukas¹, U. Hubbe¹, M.-E. Halatsch²

Affiliation

¹ Department of Neurosurgery, Albert-Ludwigs University of Freiburg, Freiburg, Germany

² Department of Neurosurgery, Ruprecht-Karls University of Heidelberg, Heidelberg, Germany

Key words

- lateral disc herniation
- METRx

Abstract



Objective: This paper aims to demonstrate the feasibility and efficacy of a minimal invasive approach by using a muscle dilator system for the treatment of lateral lumbar disc herniations.

Methods: A retrospective analysis of 38 cases with lateral lumbar disc herniations that were treated the METRx-System was performed. Patients were assessed preoperatively and postoperatively with the visual analogue scale (VAS) for leg pain. Follow up ranged from 6 to 24 months.

Results: No intraoperative complications were observed. Operation time and intraoperative blood loss were minimized. In 37 cases VAS scores were significantly lower after the procedure. A single patient had to be reoperated due to insufficient removal of the herniated disc material.

Conclusion: The reported minimal invasive technique is a safe and efficient alternative to conventional methods for the treatment of lateral lumbar disc herniations.

Introduction



Lumbar disc herniations (LDH) represent one of the most common clinical conditions requiring neurosurgical intervention. Current treatment options include several minimal invasive approaches involving percutaneous and endoscopic techniques [1]. Minimally invasive procedures aim to minimise muscle trauma and postoperative adhesion formation without affecting adequate exposure of the causative pathology.

The necessity for a less invasive approach is even greater in the case of lateral LDH affecting the extraspinal course of the nerve root. Midline approaches require a longer skin incision and excessive muscular retraction, which may result in muscle atrophy and significant postoperative back pain. Thus, in the current literature a considerable number of surgeons advocate the use of a paramedian transmuscular approach [2, 3]. In this article we report our experience with the use of a tubular retractor system (METRx, Medtronic) for the treatment of lateral LDHs. Furthermore, potential benefits and restrictions of the system are presented and discussed.

Patients and Methods



Patient population

Between January 2004 and March 2006 38 patients (mean age: 61.5 years) were treated with a minimally invasive transmuscular approach for treatment of lateral LDH. 28 patients had already been treated for at least 3 months conservatively without success. In 10 cases surgery was performed due to progression of the neurological deficits. In all cases preoperative MR images confirmed the diagnosis of a lateral LDH. Patients were assessed preoperatively and postoperatively with the visual analogue scale (VAS) for leg pain. Follow-up ranged from 6–24 months.

Technique

Under general anaesthesia patients were placed in the prone position. Cefazolin was administered prior to the skin incision. The affected level was fluoroscopically localised. A 2cm incision was performed approximately 4cm from the midline on the affected side. The feasibility of a transmuscular METRx approach for the L5/S1 level was assessed individually according to the preoperative images because of the proximity of

Bibliography

DOI 10.1055/s-2007-985143
Minim Invas Neurosurg 2007;
50: 160–162
© Georg Thieme Verlag KG
Stuttgart · New York
ISSN 0946-7211

Correspondence

V. I. Vougioukas, MD
Department of Neurosurgery
Neurocenter
Albert-Ludwigs University of
Freiburg
Breisacherstrasse 64
79106 Freiburg im Breisgau
Germany
Tel.: +49/761/270 50 01
Fax. +49/761/270 50 80
vvougio@nz.ukl.uni-freiburg.de

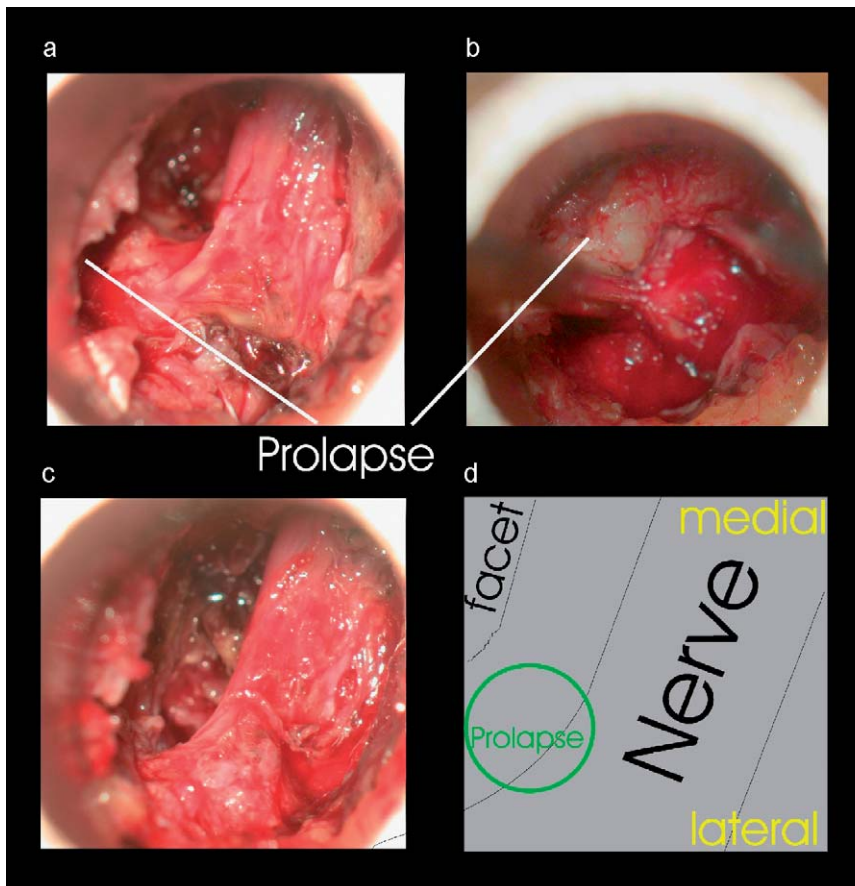


Fig. 1 Intraoperative picture before (a, b) and after (c) removal of the herniation; (d) schematic drawing of the anatomic landmarks.

the iliac crest at the L5/S1 level that may render oblique placement of the muscle dilators difficult.

Under fluoroscopic guidance a pin was used to penetrate the fascia. Subsequently the first muscle dilator was placed obliquely in an angle of approximately 20° on the facet joint. Once the dilator was firmly docked on the joint the pin was removed. The dilator is used to dissect muscle from the facet surface. This process was repeated with the larger dilators. Care was taken to keep each dilator firmly docked on the joint. Finally a METRx tube (diameter 18 mm) was implanted in order to centre the lateral edge of the joint.

For the further steps of the procedure an operating microscope was utilised. The lateral aspect of the facet was removed with the high-speed drill when needed. Muscle fibres were carefully coagulated and cut. Anatomic landmarks such as the isthmus and transverse process were detected with the use of microdissectors. In certain cases the lateral part of the ligamentum flavum was removed. Subsequently the affected nerve root and the accompanying branch of the segmental lumbar artery were localised (see • Fig. 1). Further dissection ventral to the inter-transverse membrane was avoided, because of the risk of damaging the lumbar artery and accompanying veins. After gentle cranial mobilisation of neural structures the disc space was incised and entered usually medial to the nerve root. A nerve hook was used to remove the rest of the herniated disc tissue beneath the dorsal root and ganglion. After obtaining adequate haemostasis the tube was withdrawn slowly. The walls of the dilated muscle were examined to avoid secondary bleeding. The fascia was closed with one or two absorbable sutures. The skin was closed according to the surgeon's preference.

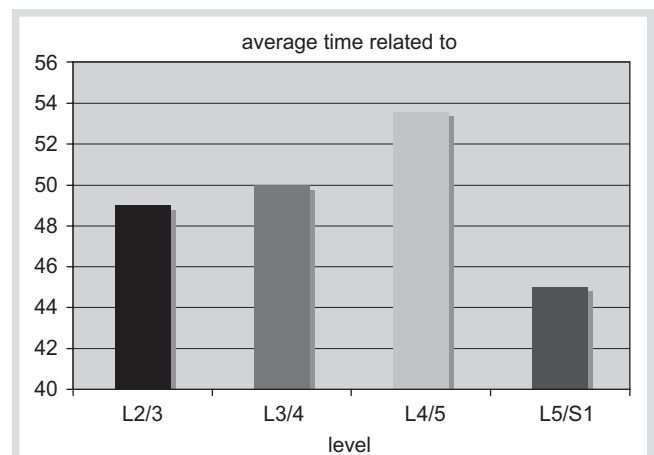


Fig. 2 Average operation time related to the level of the lesion.

Results



There were no intraoperative complications. Total operation time was on average 51 ± 15 minutes. There was no level-related variation in operation time (• Fig. 2). The postoperative VAS for leg pain improved in 37 patients compared to the preoperative data (8.5 ± 0.8 versus 1.5 ± 0.4). One patient (2.6%) had a poor outcome (VAS: 8 pre-op. versus 7 post-op.) due to insufficient removal of herniated tissue and revision surgery had to be performed 3 days later (VAS: 2 post-op.). In 9 patients pre-existing neurological deficits resolved completely. In one case a quadriplegia persisted although the patient was pain free. Intra-

operative blood loss was 30 ± 20 mL. A single superficial wound infection was treated conservatively. Postoperative need for analgesic medication was diminished in all cases. Patients were mobilised on the same day. After 72 h the patients were discharged. All patients returned to their daily activities.

Discussion

Recent advantages in minimally invasive spinal surgery aim to reduce operative iatrogenic injury without altering the goals of the traditional procedures. Numerous percutaneous and endoscopic techniques have been developed and have been used successfully for the treatment of spinal pathology [1]. The main limitation of these mainly intradiscal techniques is that they are primarily utilised to reduce discal volume and not to remove extruded disc fragments or to decompress the radix. This limitation often overcomes the advantage of minor traumatization. The superiority of endoscopic procedures over standardised microsurgical techniques for the treatment of lateral LDH remains an ongoing debate in the current literature [4–9].

The value of tubular retractor systems in the treatment of spinal pathology has been documented in a considerable number of recent publications [4–13]. The use of tubular retractors is of particular importance for procedures that are usually performed via a transmuscular approach. In this article we report about our experience with the METRx system for the treatment of lateral lumbar disc herniations. The described technique proved to be an attractive alternative to conventional midline and transmuscular approaches. The use of a tubular retractor system in the reported series resulted in a significant reduction of muscle trauma and intraoperative blood loss. The patients were mobilised a few hours after the procedure and returned to their daily activities. The above-mentioned technique is of particular importance for obese patients where longer skin incisions and excessive muscle retraction is needed in order to approach adequately lateral LDHs. For lateral LDHs at the L5/S1 level it should be noted that the proximity of the iliac crest may render oblique placement of the muscle dilators difficult. Thus the feasibility of a METRx approach for the L5/S1 level should be assessed according to the preoperative images. In addition due to the restricted operative field complete removal of the pathology may sometimes be difficult and requires familiarity with the tubular retractor system.

The transmuscular approach with a tubular retractor system for the treatment of lateral LDH is an effective and safe minimally invasive procedure that meets the results of conventional microdiscectomy, while it is associated with a minimised risk of intraoperative and postoperative complications and in overall a lower treatment cost [13, 14]. The philosophy and postoperative out-

come of the procedure is met with enthusiasm from patients and seems to be a promising method for treating lateral lumbar disc herniations in the future.

References

- 1 Kuh SU, Kim YS, Cho YE, Yoon YS, Jin BH, Kim KS, Chin DK. Surgical treatments for lumbar disc disease in adolescent patients; chemonucleolysis/microsurgical discectomy/PLIF with cages. *Yonsei Med J* 2005; 46: 125–132
- 2 Quaglietta P, Cassitto D, Corriero AS, Corriero G. Paraspinal approach to the far lateral disc herniations: retrospective study on 42 cases. *Acta Neurochir Suppl* 2005; 92: 115–119
- 3 Tessitore E, Tribollet N de. Far-lateral lumbar disc herniation: the micro-surgical transmuscular approach. *Neurosurgery* 2004; 54: 939–942
- 4 Ruetten S, Komp M, Godolias G. A new full-endoscopic technique for the interlaminar operation of lumbar disc herniations using 6-mm endoscopes: prospective 2-year results of 331 patients. *Minim Invas Neurosurg* 2006; 49: 80–87
- 5 Ruetten S, Komp M, Godolias G. An extreme lateral access for the surgery of lumbar disc herniations inside the spinal canal using the full-endoscopic uniportal transforaminal approach-technique and prospective results of 463 patients. *Spine* 2005; 30: 2570–2578
- 6 Cervellini P, Luca GP De, Mazzetto M, Colombo F. Micro-endoscopic-discectomy (MED) for far lateral disc herniation in the lumbar spine. Technical note. *Acta Neurochir Suppl* 2005; 92: 99–101
- 7 Chiu JC. Evolving transforaminal endoscopic microdecompression for herniated lumbar discs and spinal stenosis. *Surg Technol Int* 2004; 13: 276–286
- 8 Hsieh PC, Wang CH. Posterior endoscopic lumbar discectomy using a thoracopost as a tubular retractor. *Minim Invas Neurosurg* 2004; 47: 319–323
- 9 Yeung AT, Yeung CA. Advances in endoscopic disc and spine surgery: foraminial approach. *Surg Technol Int* 2003; 11: 255–263
- 10 Isaacs RE, Podichetty V, Fessler RG. Microendoscopic discectomy for recurrent disc herniations. *Neurosurg Focus* 2003; 15: E11
- 11 Epimenio RO, Giancarlo D, Giuseppe T, Raffaelino R, Luigi F. Extraforaminal lumbar herniation: “far lateral” microinvasive approach retrospective study. *Spinal Disord Tech* 2003; 16: 534–538
- 12 Greiner-Perth R, Bohm H, Allam Y. A new technique for the treatment of lumbar far lateral disc herniation: technical note and preliminary results. *Eur Spine J* 2003; 12: 320–324
- 13 Palmer S. Use of a tubular retractor system in microscopic lumbar discectomy: 1 year prospective results in 135 patients. *Neurosurgery Focus* 2002; 13: E5
- 14 Arts MP, Peul WC, Brand R, Koes BW, Thomeer RT. Cost-effectiveness of microendoscopic discectomy versus conventional open discectomy in the treatment of lumbar disc herniation: a prospective randomised controlled trial. *BMC Musculoskelet Disord* 2006; 7: 42
- 15 Obenchain TG. Speculum lumbar extraforaminal microdiscectomy. *Spine J* 2001; 1: 415–420; discussion: 420–421
- 16 Meinke AK. Totally extraperitoneal laparoendoscopic repair of lumbar hernia. *Surg Endosc* 2003; 17: 734–737
- 17 Song J, Park Y. Ligament-sparing lumbar microdiscectomy: technical note. *Surg Neurol* 2000; 53: 592–596; discussion: 596–597
- 18 Placzek R, Birken L, Morlock M, Ruther W, Schneider E. Effect of various cylinder diameters of implants for lumbar inter-corporeal spinal fusion on compressive strength on the FSU model. *Biomed Tech (Berl)* 1998; 43: 253–256
- 19 Obenchain TG, Cloyd D. Laparoscopic lumbar discectomy: description of transperitoneal and retroperitoneal techniques. *Neurosurg Clin N Am* 1996; 7: 77–85